



Kaya Kalp



Kaya kalp
Global

(AN INTEGRATED DERMATOLOGY CENTRE)

Dr. SHAILENDER DHAWA

MC 763030

8,000

Fungal patients

30,000

Vitiligo patients

10,000

Psoriasis patients

CASE STUDIES



KayakalpTM
Global



VITILIGO

A Kayakalp Case Study

Name: Rakesh Sahu
Age: 25 years
Gender: Male

Location: Malaysia
Start Date: March, 2020
Recovery Date: December, 2020

Mr. Rakesh had been suffering from vitiligo for 5 years before he contacted Kayakalp Global. By this time, he had tried allopathy doctors in Malaysia but with no relief for his condition. As a believer in the ayurvedic sciences he decided to try Ayurvedic treatment for his Vitiligo. Mr. Rakesh consulted us via telemedicine and found out about us through YouTube. On contacting us, he was assigned a health advisor who discussed the case with Ayurvedacharya Dr. S. Dhawan and a comprehensive custom treatment plan was devised for Mr. Sahu

Family history: No significant family history of diabetes, hypertension, and surgery.

Chief Complaint: The patient complained of white spots on his neck for the last 5 years.

History of the presenting illness: The patches were insidious in onset and slow in progression. The patches first appeared around the lower ear lobe and progressed to form a 5cm x 5cm white patch on the lateral aspect of the neck.

Past history: No significant past history.

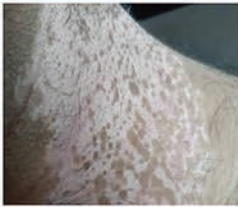Diagnosis: Leucoderma/ Vitiligo

KAYAKALP AYURVEDIC TREATMENT STARTED IN MARCH, 2020

EXTERNAL MEDICINES	INTERNAL MEDICINES
1. Re-Pigmentation ointment	1. Re-Pigmentation Capsules 2. Melanin tablets 3. Kaya-G2 4. Immunodrops

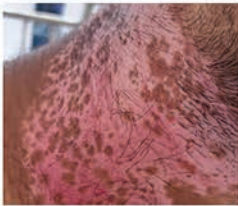
Along with medicines, patient was advised 20 minutes of yoga and other lifestyle and dietary advice for better disease management.

DISEASE PROGRESSION



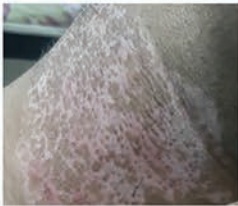MARCH, 2020

1. Kayakalp Ayurvedic treatment plan started.
2. Patient advised lifestyle and dietary modifications.



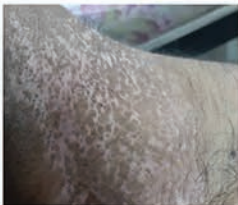APRIL, 2020

1. Color formation begins in one month
2. Outer white margins contract to come closer
3. Skin turns slight pink indicating color formation
4. Original skin spots become slightly bigger



JUNE, 2020

1. Outer white margins contract more
2. Original skin color comes back
3. Darker spots become big and join together



AUGUST, 2020

1. Darker spots increase in size
2. Healthy looking skin is visible in only 6 months
3. Near normal skin achieved.
4. Maintenance phase started



DECEMBER, 2020

1. Near total cure achieved using only ayurvedic medicines

DISCUSSION

Vitiligo is a chronic skin condition characterized by the development of white patches on the skin.

1. Our skin has colour forming cells called Melanocytes.
2. In vitiligo, our immunity starts attacking these colour forming cells.
3. Loss of colour forming cells leads to loss of pigment production in skin
4. This leads to white colour in skin where colour forming cells were killed. This condition is called vitiligo or Leucoderma.

Vitiligo is a devastating disorder causing huge mental stress in patients especially newly diagnosed patients. Problem starts when patient visit his doctor and doctor is also not very confident of treating this disease and explains that there are limited options available for treatment. Allopathy has Steroids, Melanocyl, Tacrolimus, PUVA and other Immune suppressants which are prescribed by doctors and are limited by dose-related toxicity.

At Kayakalp Global, we have perfected the art of re-pigmentation. Right combination of strength of external applications and right amount of UV exposure is key to success. Since people have less time for sun exposure, we have developed medicines which can produce perfect re-pigmentation with minimum sun exposure.

VITILIGO

A Kayakalp Case Study

Name: Rakesh Sahu
Age: 25 years
Gender: Male

Location: Malaysia
Start Date: March, 2020
Recovery Date: December, 2020

Mr. Rakesh had been suffering from vitiligo for 5 years before he contacted Kayakalp Global. By this time, he had tried allopathy doctors in Malaysia but with no relief for his condition. As a believer in the ayurvedic sciences he decided to try Ayurvedic treatment for his Vitiligo. Mr. Rakesh consulted us via telemedicine and found out about us through YouTube. On contacting us, he was assigned a health advisor who discussed the case with Ayurvedacharya Dr. S. Dhawan and a comprehensive custom treatment plan was devised for Mr. Sahu

Family history: No significant family history of diabetes, hypertension, and surgery.

Chief Complaint: The patient complained of a white patch on his right forearm for the last 4 years.

History of the presenting illness: The patch was insidious in onset and gradual in progression. The patches first appeared around the lower cubital fossa and progressed down to form a 6cm x 5cm white patch on the frontal aspect of the forearm.

Past history: Patient gives h/o chronic occupation related stress. Patient also gave history of constipation.

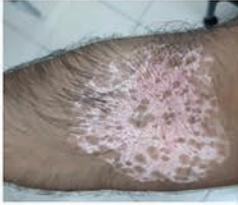Diagnosis: Leucoderma/ Vitiligo

KAYAKALP AYURVEDIC TREATMENT STARTED IN MARCH, 2020

EXTERNAL MEDICINES	INTERNAL MEDICINES
1. Re-Pigmentation ointment	1. Re-Pigmentation Capsules 2. Melanin tablets 3. Kaya-G2 4. Immunodrops

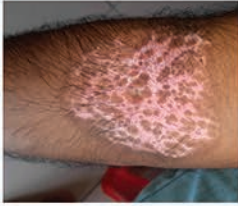Along with medicines, patient was advised 20 minutes of yoga and other lifestyle and dietary advice for better disease management.

DISEASE PROGRESSION



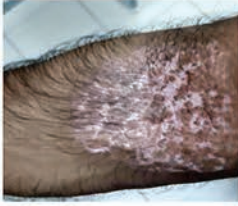MARCH, 2020

1. Kayakalp Ayurvedic treatment plan started.
2. Patient advised lifestyle and dietary modifications.



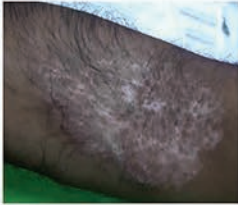
APRIL, 2020

1. Color formation begins in one month
2. Outer white margins contract to come closer
3. Skin turns slight pink indicating color formation
4. Original skin spots become slightly bigger



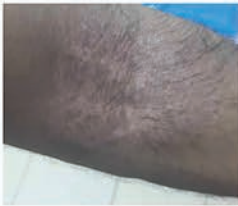JUNE, 2020

1. Outer white margins contract more
2. Original skin color comes back
3. Darker spots become big and join together



AUGUST, 2020

1. Darker spots increase in size
2. Healthy looking skin is visible in only 6 months
3. Near normal skin achieved.
4. Maintenance phase started



DECEMBER, 2020

1. Near total cure achieved using only ayurvedic medicines

DISCUSSION

Vitiligo is a chronic skin condition characterized by the development of white patches on the skin.

1. Our skin has colour forming cells called Melanocytes.
2. In vitiligo, our immunity starts attacking these colour forming cells.
3. Loss of colour forming cells leads to loss of pigment production in skin
4. This leads to white colour in skin where colour forming cells were killed. This condition is called vitiligo or Leucoderma.

Vitiligo is a devastating disorder causing huge mental stress in patients especially newly diagnosed patients. Problem starts when patient visit his doctor and doctor is also not very confident of treating this disease and explains that there are limited options available for treatment. Allopathy has Steroids, Melanocyl, Tacrolimus, PUVA and other Immune suppressants which are prescribed by doctors and are limited by dose-related toxicity.

At Kayakalp Global, we have perfected the art of re-pigmentation. Right combination of strength of external applications and right amount of UV exposure is key to success. Since people have less time for sun exposure, we have developed medicines which can produce perfect re-pigmentation with minimum sun exposure.

VITILIGO

A Kayakalp Case Study

Name: Master Yash
Age: 6 years
Gender: Male

Location: India
Start Date: October, 2004
Recovery Date: June, 2005

Yash was brought to our Faridabad branch in October, 2004. His parents were worried about white patch on the left side of his face. Yash's case is a case of segmental vitiligo that will be discussed in detail at the end. Since Yash is in the school going age group, he was first hand witnessing the side effects of Vitiligo- social out casting. The key to treatment here is to start before it spread to his scalp and hair over the white patch would turn white.

Family history: Since segmental vitiligo is not genetic, Family history is not significant.

Chief Complaint: The patient's parents complained of 2-3 white spots on the right side of the face over the course of 3 months.

History of the presenting illness:
The patches were insidious in onset and rapid in progression. The patches first appeared as a small white spot on his forehead.

Past history: No significant past history

Diagnosis: Leucoderma/ Vitiligo

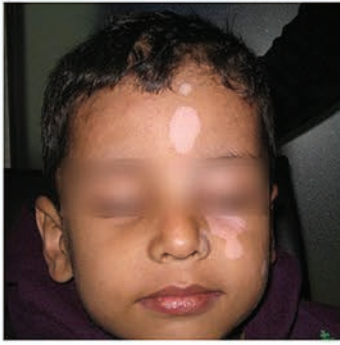KAYAKALP AYURVEDIC TREATMENT STARTED IN MARCH, 2004

EXTERNAL MEDICINES	INTERNAL MEDICINES
1. Re-Pigmentation ointment	1. Re-Pigmentation Capsules 2. Melanin tablets 3. Kaya-G2

Along with medicines, parents were advised dietary advice for better disease management.

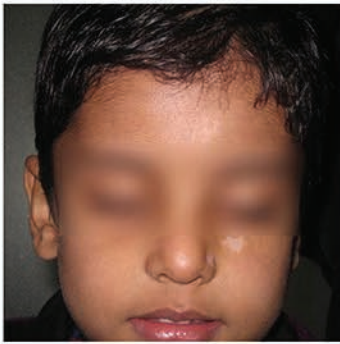Parents were also advised to let Yash receive 5-10-minute sun exposure along with re-pigmentation ointment.

DISEASE PROGRESSION



MARCH, 2004

1. Segmental vitiligo diagnosed
2. Kayakalp's integrative treatment started along with gradually progressive sun exposure.
3. Oral syrups easy for pediatric consumption prescribed.



APRIL, 2020

1. Near total recovery achieved
2. Re-pigmented skin matches the color of the surrounding healthy skin and is neither hyper pigmented not hypo-pigmented.

DISCUSSION

Vitiligo is a chronic skin condition characterized by the development of white patches on the skin.

1. Our skin has colour forming cells called Melanocytes.
2. In vitiligo, our immunity starts attacking these colour forming cells.
3. Loss of colour forming cells leads to loss of pigment production in skin
4. This leads to white colour in skin where colour forming cells were killed. This condition is called vitiligo or Leucoderma.

Vitiligo can be classified as segmental and non-segmental vitiligo. In segmental vitiligo, white patches start on one side of the body and never cross the midline. Ayurvedic texts mention wrong food combinations such as consuming milk along with meat as a cause for segmental vitiligo. It is not genetic according to modern medicine. Yash's case is considered a challenging case in the world of modern medicine.

Through integration of Ayurveda and modern medicine, Kayakalp was able to save Yash's childhood. It was imperative to start treatment in Yash's case as soon as possible since the need of the hour was to arrest the spread of the disease in its current stage. Delay in the treatment would lead to spread over his scalp and could have led to whitening of his scalp hair. Whitening of hair indicates total loss of melanin pigment and recovery is considered difficult after that.

At Kayakalp Global, we have perfected the art of re-pigmentation. Right combination of strength of external applications and right amount of UV exposure is key to success. For children we have formulated our medicines in syrup form for ease of consumption. Since people have less time for sun exposure, we have developed medicines which can produce perfect re-pigmentation with minimum sun exposure.

VITILIGO

A Kayakalp Case Study

Name: Damini Sinha
Age: 28 years
Gender: Female

Location: India
Start Date: March, 2004
Recovery Date: March, 2005

Damini presented to our Faridabad branch back in 2004. She along with her family were very tensed since she was in the marriageable age group and Vitiligo being a social stigma in India presents a challenge in a person's daily life. Lucky for us Damini was a motivated individual and with the guidance of Kayakalp Doctors and an optimistic family, she was able to achieve near total cure in a short span of time.

Family history: No significant family history of diabetes, hypertension, and surgery.

Chief Complaint: The patient complained of white spots on her chest for 2 years.

History of the presenting illness:
The patches were insidious in onset and gradual in progression. The patches first appeared on the right upper chest and progressed down in a patchy fashion to finally occupy majority of her chest.

Past history: No significant past history.

Diagnosis: Leucoderma/ Vitiligo

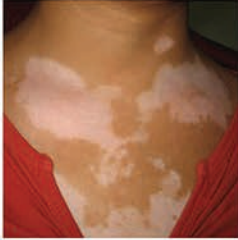KAYAKALP AYURVEDIC TREATMENT STARTED IN MARCH, 2004

EXTERNAL MEDICINES	INTERNAL MEDICINES
1. Re-Pigmentation ointment	1. Re-Pigmentation Capsules 2. Melanin tablets 3. Kaya-G2

Along with medicines, patient was advised 20 minutes of yoga and other lifestyle and dietary advice for better disease management.

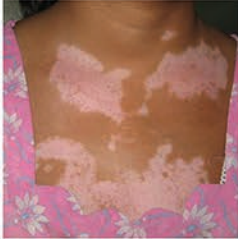She was also advised 5-10-minute sun exposure along with re-pigmentation ointment.

DISEASE PROGRESSION



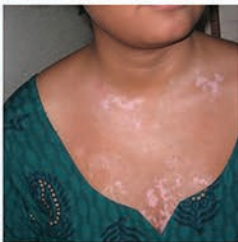MARCH, 2004

1. Rapidly spreading vitiligo diagnosed
2. Kayakalp's integrative treatment started along with gradually progressive sun exposure.



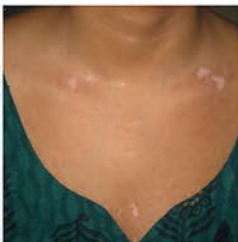MAY, 2020

1. Dark pigmented spots appear
2. Outer margins seen contracting
3. Middle white patch already recovered



SEPTEMBER, 2020

1. Dark pigmented spots enlarge and join
2. Re-pigmented skin matches surrounding skin



DECEMBER, 2020

1. Near total recovery has been achieved with sun exposure and integrative treatment approach.

DISCUSSION

Vitiligo is a chronic skin condition characterized by the development of white patches on the skin.

1. Our skin has colour forming cells called Melanocytes.
2. In vitiligo, our immunity starts attacking these colour forming cells.
3. Loss of colour forming cells leads to loss of pigment production in skin
4. This leads to white colour in skin where colour forming cells were killed. This condition is called vitiligo or Leucoderma.

Damini's case is a case of every other Indian female in the marriageable age group. Vitiligo is a cause of social stigma and outcast in most communities of the world. Similarly in Damini's case, she along with her parents was worried of the same. Luckily for us she was dedicated throughout the journey and never deviated. With the adequate sun exposure and the right combination of herbal medicines Kayakalp's treatment worked wonders for her.

At Kayakalp Global, we have perfected the art of re-pigmentation. Right combination of strength of external applications and right amount of UV exposure is key to success. Since people have less time for sun exposure, we have developed medicines which can produce perfect re-pigmentation with minimum sun exposure.



 Clinic Site No 5, opp Drishti Eye Centre,
Sector 17, Faridabad, Haryana 121002

 kayakalpglobal.com

 +91 95 99 79 44 33

Follow us on :     